The journal of
PROSTHETIC AND IMPLANT DENTISTRY
Official Publication of Indian Prosthodontic Society
Kerala State Branch

PORCELAIN LAMINATE VENEER- A NOVEL APPROACH FOR ANTERIOR AESTHETIC REHABILITATION

*Ambili Ravindran P.

*Senior lecturer, Department of Prosthodontics & Crown and Bridge, Indira Gandhi Institute of Dental Sciences, Kothamangalam, IND. Corresponding Author: Dr Ambili Ravindran P., Email: dr.ambiliravindran@gmail.com

https://doi.org/10.55231/jpid.2026.v09.i02.06

Abstract

For a dentist, treating a patient's healthy but unsightly teeth has proven to be very difficult. One of the most aesthetically pleasing ways to have a more beautiful and pleasing smile is with porcelain laminate veneers. The location, shape, size, and color of teeth can all be changed using porcelain veneers. They only need a small amount of surface enamel reduction (0.5–0.7 mm) to prepare the teeth. The primary subject of this study is a patient who had repeated restorations done on an anterior region with composite. The patient received porcelain laminate veneers for aesthetic correction in the maxillary anterior region with good cosmetic results, which lends credence to the notion that minimally invasive porcelain laminate veneers could become a conservative and adaptable ally in the aesthetic dentistry domain.

Keywords: Aesthetics, Porcelain laminate veneers, Composite restoration.

Introduction

A confident smile is the most beautiful accessory somebody can have. A self-assured smile is an essential aspect of each person's personality. People are starting to place a higher importance on having a gorgeous, healthy smile. Cosmetic dentistry has developed, giving dentists additional options for conservative and aesthetically acceptable repair techniques[1,2].

There has always been difficulty in restoring unsightly anterior teeth because it involves a lot of healthy tooth tissue and has a negative impact on the pulp and gingiva. A more conservative option for enhancing the appearance of anterior teeth than full coverage restorations are laminate veneers. The available treatments that restore and optimize the appearance of anterior teeth are the least intrusive ones.

In order to enhance a tooth's appearance, extremely thin porcelain shells known as porcelain veneers or dental porcelain laminates are luted to the front of teeth. A thin porcelain shell is securely attached to a tooth using its bonding power of material. When porcelain is effectively bonded to a tooth, its naturally fragile nature transforms into one of extreme robustness and durability[3].

Veneers are a dentist's suggested and frequently requested treatment due to their mechanical, aesthetic, and biocompatible properties, as

well as their ability to preserve tooth structure, last a long time, be dependable, and improve bonding strength[4]. This article covers a case where porcelain laminate veneers were used conservatively to correct a stained anterior restoration in order to attain the desired cosmetic results.

CASE REPORT

OUTLINE OF THE CASE

DIAGNOSIS

A female patient, age 24, came to the prosthodontics department to have her upper anterior teeth restored in an aesthetic manner. Her goal was long-term repair, with better aesthetics being her main priority. The results of the clinical evaluation showed that the left and right central incisors were cracked at the incisal area, and composite was used to reconstruct them. The patient's past dental history indicated that the discoloration of the aesthetic restoration caused the central incisors to undergo repeated procedures over the course of four years.

Every standard clinical and radiological examination fell well within acceptable bounds. An overbite of 3 mm and an overjet of 2 mm were noted during the intraoral examination. When the patient initially arrived, they had a good periodontal state, a thin gingival biotype, a medium frenal attachment (Class II), and adequate dental hygiene.

The patient was given information on a number of treatment options, including laminates, a full crown, and a repeat of a composite restoration. After being informed of the benefits and drawbacks of each therapy, the patient decided to have porcelain laminate veneers (PLV).

Treatment plan

A comprehensive case history, clinical assessment, radiological analysis, and any additional required research were completed. The cost aspect was also assessed. The treatment approach chosen was a modest tooth preparation for laminate with quick provisionalization.

Procedure

Prior to undertaking any interventional procedures, a thorough oral prophylaxis was completed to ensure optimal periodontal health. Subsequent diagnostic evaluation included radiographic imaging to assess the underlying structures. Based on clinical and radiographic findings, the treatment plan for the maxillary right and left incisors involved the incorporation of an incisal overlap design with a proximal wraparound extension to enhance retention, stability, and functional integration.

First, the Veneer depth cutting (LVS1) bur was used to place the labial surface's initial depth orientation grooves. Using a long, round-end tapered standard grit diamond bur, a chamfer finish and 0.5 mm labial reduction were obtained with a sulcular extension of 0.2–0.3 mm. The contact region was located 0.2 mm labial to the mesial and distal finish lines. A gingivally sloping 1 mm incisal reduction from the labial was carried out. A rounded chamfer was created in the lingual enamel down to a depth of 0.5–1 mm. To reduce postoperative sensitivity and to achieve good bonding, the overall reduction was limited to the enamel.

Gingival retraction was achieved by impregnating a retraction cord (Ultrapak Dental retraction cord #00) with hemostatic gel (Hemostal GelTM, Prevest DenPro, USA) for a duration of two minutes (Fig:1). Making use of vinyl polysiloxane (Photosil TM, India, DPI) Final impressions were made in a custom tray and submitted to the laboratory after a two-stage putty wash procedure (Fig:2). choose a shade. Provisionals were created using composite because the preparation was in an aesthetic area.

Using the heat press method, veneers were created from lithium disilicate material (IPS e.max Press, Ivoclar Vivadent, Lichtenstein). After the laminate veneers were received from the laboratory, a few days later a clinical try-in was conducted to assess the protruding interferences, contacts, color match, shape, and marginal fit. Following verification of proper clinical seating and confirmation of the absence of occlusal interferences along the lingual surfaces, the veneers were deemed clinically acceptable and subsequently approved for definitive bonding.

Fig.1: Tooth preparation followed by gingival retraction

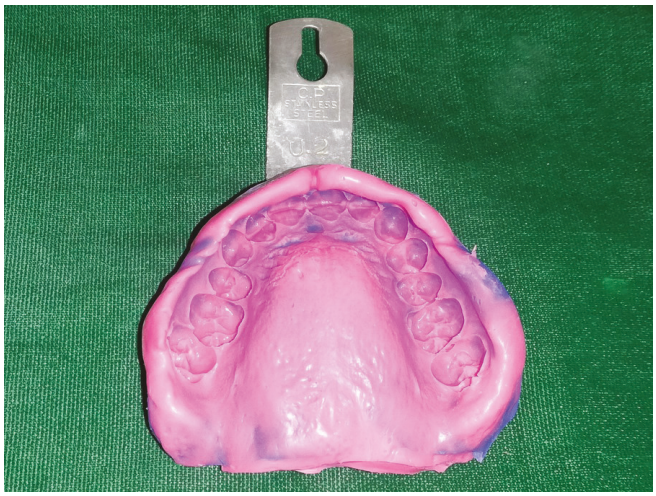

Fig.2: Recorded impression with polyvinylsiloxane impression material in putty and light body consistency.

On the day of cementation, two days following the try-in, the veneers' intaglio surface was etched using Ivoclean or 5% hydrofluoric acid (IPS Ceramic Etching Gel, Ivoclar Vivadent AG) for 20 seconds. Following cleaning and drying, silane coupling agent (Ivoclar Vivadent, Monobond® N) was used. After etching the prepared tooth surfaces for 15 seconds with 35% phosphoric acid (ScotchbondTM, 3M ESPE), the surfaces were washed with pumice slurry, rinsed with water, and left to air dry. Subsequently, a bonding agent was meticulously applied to the prepared tooth surfaces in accordance with the manufacturer's recommendations, ensuring optimal adhesion for the planned restorative procedure. (Single Bond Universal Adhesive, 3M ESPE).

Using an adhesive tip applicator, a light cure resin luting agent of transparent shade (RelyXTM Veneer cement, 3M ESPE) was applied to the porcelain veneers' intaglio surface and then carefully set on the teeth. Following a five-second tack-curing phase, the restoration margins were carefully evaluated to ensure complete seating and proper adaptation to the prepared tooth structure. After removing extra luting cement, each tooth underwent light curing for 30 seconds to ensure full polymerization. Occlusal

Fig.3: Cementation of veneer

interferences were carefully evaluated following veneer placement (Fig:3). Proximal contacts were assessed using dental floss to verify proper contact integrity, and the results were deemed clinically satisfactory. (Fig:4). To optimize the long-term success of the restorations, the patient was advised to maintain rigorous oral hygiene measures, avoid direct incisal loading on hard foods, and comply with a structured recall regimen at one week, one month, six months, and annually for continued monitoring and maintenance. (Fig:5)

Fig 4 and Fig. 5: Preoperative and post operative photograph

Discussion:

Research indicates that porcelain veneers are a good conservative and aesthetically pleasing treatment choice. The advantages of employing these restorations include their strong resistance against abrasion, stability, reduced chance of generating irritation or sensitivity, less cytotoxicity, and biological acceptability to the body due to their higher chemical stability. Additionally, they take a cautious stance and refrain from removing too much natural teeth[4]. Owing to their uniformly glazed surface, these restorations show less plaque accumulation and easier cleaning. The thinness of the ceramic (0.3-0.5mm) makes the veneers brittle even before they are glued. However, once attached to the scratched enamel surface, they become more robust and blend in with the tooth structure. Nevertheless, they do have certain drawbacks. Porcelain laminate veneers cannot be applied to areas with extreme crowding, loss of enamel, or parafunctional habits. For teeth with dark stains, veneers are not the ideal repair. When veneers are used to treat worn-down teeth with considerable dentin exposure, improper bonding onto pre-existing composite restorations can lead to veneer failure. The tendency of heat fluctuations to produce veneer cracking when the porcelain is thin and the luting composite is thick is another risk factor. When the ceramic and luting composite thickness ratios are not larger than three to one, the least degree of cracking is observed.

The patient's selection is crucial to the effectiveness of porcelain veneers. in present case the patient's young age and their inclination towards wear, slight fractures, and discoloration,

the lifespan of the composite materials used in this case is dubious[5,6]. In this case, porcelain laminate veneers were the best course of action because the patient had a normal overjet and overbite, a nice smile line, no parafunction, and sufficient enamel. Modern prosthodontics has undergone a paradigm change to support the growing interest in using conservative restorative options. The provision of minimally invasive dentistry has been under more scrutiny and demand in recent literature in order to give excellent care with the least amount of tooth structure removed. In order to improve strong bonding, retention, aesthetics, and strength, it has thus been considered a workable strategy to preserve the patient's tooth structure[7,8].

Conclusion:

The literature has described a number of methods for treating anterior shattered teeth, including full-contour porcelain crowns, porcelain laminate veneers, and composite resin restorations. The biggest disadvantage of composite restorative materials is that they require numerous follow-ups and become stained with time, despite being less expensive and time-consuming. Laminated veneers are a more cautious alternative.

References

1. Tesvikiye cad. No. 143, Bayer apt. Kat 6, Nisantasi, Istanbul 34367, Turkey: Porcelain Laminate Veneers: Minimal Tooth Preparation by Design Galip Gu¨rel, MSc. Dent Clin N Am 51 (2007) 419–43. doi:10.1016/j.cden.2007.03.007
2. R. K. Morita, M. F. Hayashida, Y. M. Pupo, G. Berger, R. D. Reggiani, and E. A. G. Betiol. Minimally Invasive Laminate Veneers: Clinical Aspects in Treatment Planning and Cementation Procedures. Volume 2016, Article ID 1839793, 13 pages http://dx.doi.org/10.1155/2016/1839793
3. Abu-Hussein Muhamad, Mai Abdulgani, Jabareen Ayah, Shehadee Ameer, Azzaldeen Abdulgani. Porcelain laminates: the Future of Esthetic Dentistry. IOSR Journal of Dental and Medical Sciences (IOSR-JDMS). Volume 16, Issue 5 Ver. XI (May. 2017), PP 68-75. DOI: 10.9790/0853-1605116875
4. Hari M, Poovani S. Porcelain laminate veneers: A review. J Adv Clin Res Insights 2017; 4:187-190
5. Prasanna R. Sonar, Aarati S. Panchbhai, Sanket Vaidya.Anterior Aesthetic Rehabilitation for Midline Diastema Closure With Veneers: A Case Report. Cureus 15(11): e49704. DOI 10.7759/cureus.49704.
6. Dhanashree A. Minase, Seema Sathe, Anjali Bhoyar, Chinmayee Dahihandekar, Tanvi Jaiswal.Porcelain Laminate Veneers: A Case Report. Cureus 15(1): e34220. DOI 10.7759/cureus.34220.
7. Sheetal Vijaya, Shilpa Vijaya, Meghan J Shetty.Management of Midline Diastema in a Young Adult With Minimal-Thickness Porcelain Laminate Veneers. Cureus 15(7): e41904. DOI 10.7759/cureus.41904
8. Peumans M, Van Meerbeek B, Lambrechts P, Vanherle G: Porcelain veneers: a review of the literature. J Dent. 2000, 28:163-77. 10.1016/s0300-5712(99)00066-4.