The journal of
PROSTHETIC AND IMPLANT DENTISTRY
Official Publication of Indian Prosthodontic Society
Kerala State Branch

INTEGRATING PNAM APPLIANCE THERAPY FOR IMPROVED POST-SURGICAL AESTHETICS IN NON-SYNDROMIC UNILATERAL CLEFT MANAGEMENT

*Aditi Verma, **Saumyendra Vikram Singh, ***Deeksha Arya

*Senior Resident, **Professor, ***Additional Professor, Department of Prosthodontics, Faculty of Dental Sciences, King George's Medical University, Lucknow, Uttar Pradesh, India. Corresponding Author: Dr. Saumyendra Vikram Singh, E-mail: saumyendravsingh@rediffmail.com

https://doi.org/10.55231/jpid.2026.v09.i02.04

Abstract

Cleft lip and palate are common congenital anomalies, with profound aesthetic and functional implications both in the short and long term. The primary concern in infancy is to achieve optimal systemic health of the baby, so that reconstructive surgery can be performed and the cleft segments approximated and molded to facilitate good post-surgical aesthetic results. In the present case study, significant objectively assessed improvements were observed in the infant's feeding, weight gain, approximation of cleft segments, and aesthetic outcome through the proper use of a feeding plate and presurgical naso-alveolar molding (PNAM). Parent cooperation and lactation education were key to treatment success.

Keywords: Presurgical nasoalveolar molding; Unilateral cleft lip and palate; Infant orthopedic appliances; Aesthetic outcome; Cleft rehabilitation

INTRODUCTION

Cleft lip and palate are one of the commonest congenital deformities. They can be found as a single entity or in the syndromic form.[1] Incidence of cleft lip and palate in North India is approximately 1 in 600 to 800 live births.[2] With advancements in technology, prenatal assessment of clefts is possible, which helps in formulating treatment plans and mentally preparing parents for the condition. Literature suggests that multiple etiological factors, like genetics, maternal physiological factors, and smoking, are responsible for cleft lip and palate.[3]

Problems associated with cleft lip and palate infants include impaired suckling because of a lack of negative pressure, due to direct oro-nasal communication, and affected appearance with adverse social and psychological implications for the patient and parents. Slow growth and development of infants occur due to inadequate feeding because of factors like excessive air

intake during feeding and requirement of a longer feeding time due to muscle fatigue.[4] Regurgitation, aspiration, and upper respiratory tract infections are well-known risks. The motor pattern of speech development gets impaired as proper closure of oro-nasal passage is required to produce specific sounds. The cleft leads to disruption in growth and appearance of the mid-facial region, specifically affecting the upper lip and nose. This requires multiple corrective surgeries starting from when the individual is a few months old, and may still produce less than satisfactory results, if naso-alveolar molding is not done.

Therefore, treatment is multidisciplinary, including the Orthodontist, Prosthodontist, Plastic Surgeon, and Speech Therapist. The role of the prosthodontist in the management of cleft lip and palate patients has changed significantly in the past 40 years.[5] Initial naso-alveolar molding by the prosthodontist and parent education about lactation are the first steps towards successful long-term treatment of such cases. Pre-surgical naso-alveolar molding (PNAM) makes appropriate alterations to the feeding plate, approximating and optimally positioning the palatal segments, decreasing cleft size. Subsequently, the nasal deformity comprising of depressed columella and/or meganostril is addressed when the soft tissues are still plastic and amenable to forces applied by molding. Absence of molding can lead to visible scarring and contracture at the cleft site. Molding leads to a better immediate and post-surgical aesthetic outcome, apart from obvious improvement in systemic parameters due to obturation of the communication by the feeding plate. Such appliances cannot be successful without the cooperation and understanding of parents. Further, counseling parents regarding feeding is of utmost importance in managing such cases. A case study harmonizing the above factors leading to a successful outcome is described.[6]

CASE REPORT

A 10-day-old patient with a congenital right unilateral complete cleft involving the lip, alveolus, and hard as well as soft palate, was referred from the Department of Pediatrics for fabrication of a feeding plate. Because of insufficient feed, the baby was weak and had poor growth. At the time of birth, the weight of the newborn was 3.10 kg, which decreased in the first week to 2.50 kg.

An initial examination revealed a Veau's class III defect (Figure 1a, 1b). Primary impression was made using addition silicone putty (Zhermack Hydro Ride, Italy), with the infant lying in face down position and patency of airway ensured by the infant crying. Impression was evaluated, and cast poured in dental stone (Kalstone, Kalabhai Karson Pvt Ltd, India). After blocking undercuts on the cast and providing the missing palatal and alveolar segments with proper contour using modelling wax, a feeding appliance was fabricated using autopolymerizing polymethyl methacrylate (DPI cold cure, Mumbai). The posterior extension of the feeding plate was ensured visually and by the absence of gag stimulation. Intaglio surface of the feeding appliance was finished and polished to avoid abrading the delicate mucosa, ensuring that it did not extend into the palatal or alveolar defect, to facilitate gradual approximation of the palatal segments. The posterior margin of the feeding plate was kept paper-thin. A small mushroom-shaped retentive button of clear acrylic resin was made on the feeding plate, in the centre of the alveolar cleft site, at a 45-degree outward angle to the occlusal plane. This was to ensure that the button did not interfere with the lip seal during suckling.

Two elastics of 3/16" (Dentosmile Orthodontic

Intraoral Latex Elastics, India), were wound on the button with medical tapes (0.25 inches wide, Transpore tape, 3M India Limited), extended slightly upward and laterally, and attached to Base Tapes (0.5-1.5 inches wide, Micropore, 3M India Limited) which were stuck on the cheek, about a finger width below the eye. This mechanism helped retain the feeding plate and provide anchorage for subsequent naso-alveolar molding. Proper suckling with no gagging and training of parents in positioning the plate were ensured before delivering the prosthesis. Medical tape extending between the nasolabial lines to approximate the cleft lip segments from the first appointment helped bring the lip segments together.

Parents were informed about the importance of feeding in helping the baby reach adequate parameters for the lip surgery. They were instructed to use a milk bottle with milliliter markings and a soft, long nipple, to record the amount of milk consumed, to monitor the ease or difficulty of suckling, and to keep the baby in a semi-reclining position while feeding to help direct the milk posteriorly toward the oropharynx without regurgitation. Such instructions, with regular reminders, become even more crucial in a context where the parents are socio-economically or educationally disadvantaged. Weekly follow-ups included weight measurements to assess growth and cleft space measurements on a cast to evaluate appliance efficacy.

Fig. 1a. At 10 days of age **1b.** Close-up view at 10 days of age **1c.** PNAM appliance in place with lip taping. **1d.** PNAM appliance **1e.** Post PNAM view at 5 months of age **1f.** Close-up view at 5 months of age

Alveolar molding was initiated one week after delivering the feeding plate, ensuring the baby was comfortable and the caretaker was inserting the appliance properly. One millimeter of silicone-based relining material (Detax mollosil soft liner, DETAX GmbH, Ettlingen, Germany) was added to the feeding plate in areas where the alveolar segments needed to be directed away, and a corresponding 1 mm of acrylic was removed from the plate in regions where the alveolar segments needed to move into position. The goal was to move the larger alveolar segment inward and toward the smaller segment, and to move the smaller segment outward (anteriorly) and toward the larger segment until they approximated each other and were in a better position for surgical union. Therefore, these sequential additions and removals were performed weekly.

After the gap between the alveolar segments was reduced to about 6mm, a swan's neck shaped nasal stent was bent from a 19-gauge stainless steel wrought wire, with one end inserted into the feeding plate near the retentive button, and the

Fig.2a Post-operative view

2b Post-operative close-up view of nasal elevation and lip closure

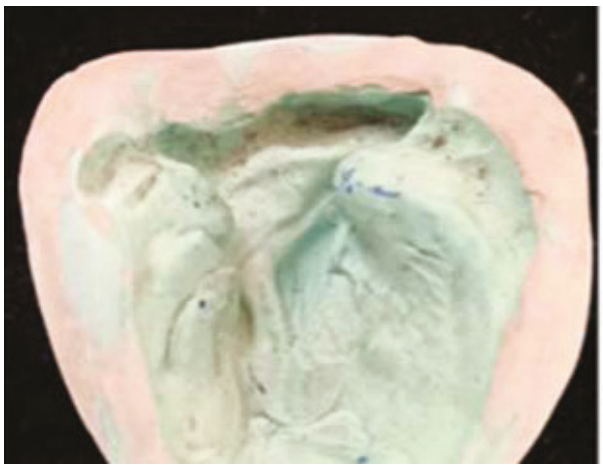

2c Cast of Intraoral cleft at time of presentation

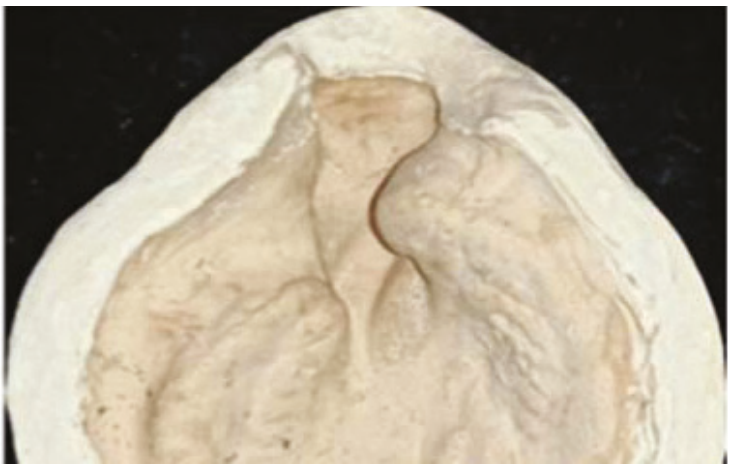

2d Cast of Intraoral cleft before surgery

other end passively contacting the centre of the mucosal aspect of the affected ala. The shape of the wire ensured enough clearance from the cleft segment for lip taping, and an outward force on the ala when activated. The tip of the stent was covered with an inner layer of autopolymerizing polymethyl methacrylate and an outer layer of soft liner, in the shape of a small bead. The nasal stent was activated outward and forward to produce a slight blanching of the ala. The purpose was to pull the deviated bridge of the nose towards the middle of the face and to add contour to the flattened ala (Figures 1c, 1d). Nasal and alveolar molding was continued at 7–10-day intervals till the infant turned 20 weeks old (Figure 1e, 1f). By then, positive changes in the affected oral and facial region and systemic parameters had taken place (Tables 1,2). Lip surgery was performed when the infant was 5 months old, with a satisfactory outcome (Figures 2a,2b,2c,2d). The baby was in constant follow-up and observation till writing this report, as the role of multiple specialties is important for long-term functional and aesthetic success.

Table 1-Weight and age comparison

S.No.	Age	Weight
1	Birth	3.10kg
2	1 month	3.90kg
3	2 months	5.50kg
4	3 months	6.50kg
5	4 and 5 months	8.00kg

Table 2-Approximation of alveolar cleft space

S.No.	Age	Anterior Cleft gap
1	Birth	15mm
2	1 month	13mm
3	2 months	10mm
4	3 months	7mm
5	4 months	6mm
6	5 months	4mm

DISCUSSION

The results with PNAM therapy in this non-syndromic unilateral cleft lip and palate case were highly encouraging. A notable reduction in the alveolar cleft width from 14 mm to 4 mm was observed, along with a visible improvement in nasal symmetry and contour over a period of 5 months. These improvements support the effectiveness of PNAM as an essential pre-surgical adjunct in cleft care. Two critical factors that contributed to this success were early initiation of therapy and active parental cooperation.[1,2]

Early initiation of PNAM therapy is widely regarded as pivotal to its success. Newborn tissues are more moldable due to the elevated levels of maternal estrogen, which increase hyaluronic acid in the cartilage and connective tissues. This window of plasticity offers the best opportunity to reshape the nasal cartilage, align alveolar segments, and support optimal soft tissue adaptation. Delayed initiation, on the other hand, may result in reduced tissue responsiveness, making it more difficult to achieve desired aesthetic and functional results. It can also prolong the total treatment time and may necessitate more extensive surgical intervention later.[7]

Parental involvement cannot be overemphasised in PNAM therapy. The parents are responsible for correctly placing the appliance multiple times a day, maintaining hygiene, monitoring feeding and growth, and ensuring timely follow-up appointments. These responsibilities are more efficiently managed by literate and motivated caregivers who understand the nature and goals of the treatment. At our center, we

have observed a direct correlation between parental awareness and treatment success. Providing comprehensive training to parents—including how to place lip taping, secure the appliance, feed in upright positions, and track weekly weight gain—has proven beneficial. Moreover, parental education plays a larger societal role in reducing the stigma surrounding cleft conditions by spreading awareness and improving community acceptance.[8]

Despite the advantages, PNAM therapy is not without its complications. The most common include tissue ulceration due to pressure from the appliance or faulty placement/ removal, irritation from taping, and poor appliance retention. These can usually be managed through timely recall examinations, use of biocompatible soft liners, and reinforcing instructions to the caregiver. A dedicated and trained team monitoring these factors significantly reduces adverse effects. The "Rule of 10s" is a widely accepted surgical guideline that recommends cleft lip repair be undertaken when the child is at least 10 weeks old, weighs 10 pounds (approximately 4.5 kg), and has a hemoglobin level of 10 g/dL. PNAM therapy is ideally completed before this timeline, aligning with these criteria and optimizing surgical outcomes.[9]

There exists a divergent school of thought that questions the significance of PNAM. Critics argue that the effects of PNAM may be short-term and that nasal morphology can relapse post-surgery without continued nasal support. Some studies also suggest that surgical techniques alone may yield comparable results in experienced hands. However, proponents counter that PNAM minimizes tissue tension during surgery, improves surgical precision, and reduces the need for extensive nasal revision later.[6,7,11]

It has been stated that educating parents about causative factors, the significance of management, and follow-up of the condition during the prenatal period often reduces parental anxiety or depression and motivates them to seek early treatment. It also improves the psychological and cosmetic outcome for patients.[10,11] Patel et al concluded that pre-surgical nasoalveolar molding helped reduce the cleft gap, improve arch form, approximate lip segments, and distinctly improve the nose morphology by correcting flattened nasal wings.[6]

At the conclusion of PNAM therapy, primary cheiloplasty (cleft lip repair) is the standard surgical procedure undertaken. Depending on the case and surgeon's preference, techniques like Millard's rotation advancement or Tennison-Randall's triangular flap method may be employed. The goals are to achieve proper muscular continuity, symmetrical nasal and lip contours, and a favorable long-term aesthetic outcome. The groundwork laid by PNAM in approximating the segments and improving nasal symmetry significantly contributes to the success of this surgery.[2,3,6,7]

CONCLUSION

Early institution of treatment, regular recalls for molding, weekly cleft dimension and weight measurements, and parental counseling, education, and compliance are extremely important in improving the prognosis of PNAM in cleft lip and palate babies. PNAM therapy remains a cornerstone in modern cleft care, especially when initiated early and supported by well-informed, cooperative caregivers. Its multifactorial benefits—ranging from surgical ease to societal integration—underscore its relevance in both clinical and psychosocial domains.

REFERENCES

1. Venkatesh R. Syndromes and anomalies associated with cleft. Indian J Plast Surg. 2009;42: S51-5.
2. Vyas T, Gupta P, Kumar S, Gupta R, Gupta T, Singh HP. Cleft of lip and palate: A review. J Family Med Prim Care. 2020;9:2621-5.

3. Muhamad AH, Azzaldeen A, Watted N. Cleft lip and palate: a comprehensive review. Int J Basic Appl Med Sci. 2014;4:338-55.
4. Thomas DT. Clinical maxillofacial prosthetics. 1st ed. Chicago: Quintessence Publishing Co Inc; 2000.
5. Beumer J, Curtis TA, Marunick MT. Maxillofacial rehabilitation: prosthodontic and surgical management of cancer-related, acquired, and congenital defects of the head and neck. 3rd ed. Chicago: Quintessence Publishing Co Inc; 2011.
6. Patel D, Goyal R. Pre-surgical nasoalveolar moulding in a patient with unilateral cleft of the lip, alveolus and palate: case report. J Plast Reconstr Aesthet Surg. 2012;65:122-6.
7. Grayson BH, Santiago PE, Brecht LE, Cutting CB. Presurgical nasoalveolar molding in infants with cleft lip and palate. Cleft Palate Craniofac J. 1999;36(6):486-98.
8. Nagaveni NB, Chiranjeevi H. Presurgical nasoalveolar molding in cleft lip and palate infants: a narrative review. Epidemiol Int J. 2024;8(2):000277.
9. Garcés Alvear GA, Moreno Soza MIB, Ormeño Quintana ADP, Gutiérrez Melis CM. Complications during Grayson presurgical nasoalveolar molding method in nonsyndromic infants with complete unilateral cleft lip and palate. J Craniofac Surg. 2021;32(6):2159-62.
10. Shirol SS. Sociocultural beliefs and perceptions about cleft lip palate and their implications in the management, outcome, and rehabilitation. J Cleft Lip Palate Craniofac Anomal. 2018;5:4-5.
11. Jahanbin A, Alizadeh FL, Bardideh E, Sharifi S, Nazari MS. Does presurgical nasoalveolar molding reduce the need for future bone grafting in cleft lip and palate patients? A systematic review and meta-analysis. J Craniofac Surg. 2022;33(7):2095-9.