The journal of
PROSTHETIC AND IMPLANT DENTISTRY
Official Publication of Indian Prosthodontic Society
Kerala State Branch

SEAMLESS SMILE TRANSITION: UTILIZING ESSIX RETAINER WITH PONTIC AS AN INTERIM PROSTHESIS IN ANTERIOR IMPLANT THERAPY — A CASE REPORT

*Nidhi Shree, **Mukesh Kumar Goyal, ***Geeta Paul, ****Shalini Chauhan

*Post Graduate Student, ** Professor and Head of the Department of Prosthodontics and Crown and Bridge ***Professor, ****Senior Lecturer, Department of Prosthodontics and Crown and Bridge, Inderprastha Dental College and Hospital, Sahibabad, Ghaziabad - 201 010 | Corresponding author: Dr. Mukesh Kumar Goyal. Email: dr.mukeshgoyal@gmail.com

https://doi.org/10.55231/jpid.2025.v09.i01.05

Abstract

Tooth loss in the anterior maxilla is often associated with significant aesthetic, functional, and psychological concerns. During the healing phase after implant placement, it becomes essential to provide a temporary prosthetic solution that maintains appearance and protects the surgical site. Among the various interim options, Essix retainers with integrated pontics offer a conservative, minimally invasive, and esthetically acceptable alternative. This case report describes the prosthetic management of a 39-year-old male patient who presented with a missing maxillary left central incisor due to trauma. After clinical and radiographic assessment confirmed suitability for implant placement, a 3.5 mm × 11.5 mm titanium implant was placed under local anesthesia. To maintain the space and esthetics during osseointegration, an Essix retainer with a prefabricated acrylic pontic was fabricated and delivered. The patient was educated about maintenance, hygiene, and follow-up protocols. During periodic reviews, the healing was uneventful, and the patient expressed satisfaction with comfort and appearance. This report highlights the role of Essix retainers as a simple, cost-effective, and patient-friendly option for interim prosthesis in anterior implant therapy, especially when soft tissue preservation and esthetics are priorities during the transitional phase.

Keywords: anterior implant, esthetic rehabilitation, essix Retainer, interim prosthesis, pontic, transitional appliance

Introduction

Tooth loss in the anterior maxilla poses significant aesthetic and psychosocial challenges. During the osseointegration period following implant placement, provisional prostheses play a pivotal role in preserving appearance, phonetics, and patient confidence. An ideal interim solution should be minimally invasive, visually discreet, and avoid pressure on the surgical site. The

Essix retainer with an integrated pontic is one such approach, offering high patient acceptance and fabrication ease.[1] This case report outlines its use in managing left central incisor during implant healing, highlighting its benefits over traditional interim options.

Case Presentation

A 39-year-old male patient presented to the Department of Prosthodontics and Crown & Bridge with a missing maxillary left central incisor due to previous trauma. The patient expressed a strong desire for an aesthetic and fixed long-term replacement, opting for an implant-supported prosthesis.

Extraoral examination revealed no significant abnormalities (Figure 1). Intraorally, the patient presented with a healed edentulous ridge in the region of left central incisor with clinically and radiographically adequate bone volume confirmed via CBCT for implant placement. The patient maintained satisfactory oral hygiene and there were no systemic or local contraindications to implant therapy.

Based on the clinical and radiographic evaluation, the treatment plan included the placement of a dental implant for left central incisor to restore function and aesthetics. An interim prosthesis was planned to maintain the appearance and space during the osseointegration period. Following successful healing and integration of the implant, a definitive implant-supported crown would be fabricated and delivered.

Implant placement was carried out under local anesthesia using standard aseptic protocols. A 3.5 mm × 11.5 mm titanium implant (Adin) was placed with satisfactory primary stability. Optimum initial torque of 35 N/cm2 was obtained. Cover screw was secured, and the site was sutured for primary closure. Postoperative healing was uneventful.

Fabrication Of Interim Prosthesis

To preserve esthetics and maintain the edentulous space during the osseointegration period, an Essix vacuum-formed matrix retainer incorporating a pontic for left central incisor was fabricated. A preoperative maxillary impression

Figure 1: Intraoral preoperative view showing the edentulous space for left central incisor prior to interim prosthesis delivery

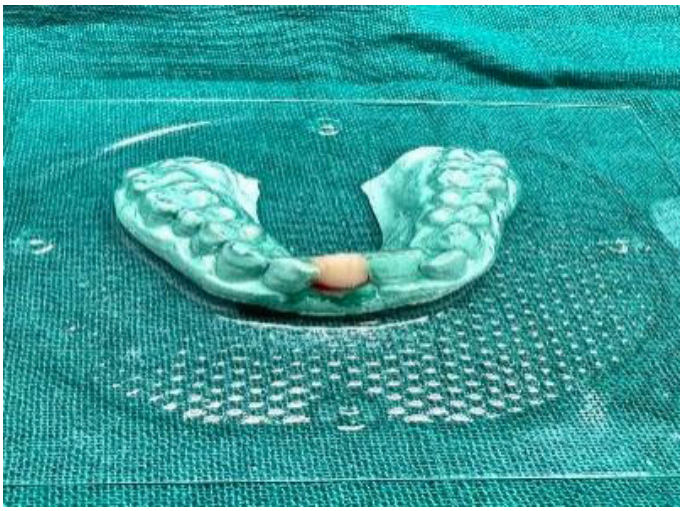

Figure 2: Clear vacuum-formed Essix retainer with anterior pontic placed on the maxillary cast

was made using an irreversible hydrocolloid material (Tropicalgin, Zhermack SpA, Italy). The impression was poured in Type III dental stone (Kalabhai Kalstone, India) to produce a working cast.

To replicate the missing maxillary left central incisor, a preformed acrylic denture tooth (Pyrax, India) was selected. These teeth are composed of cross-linked polymethyl methacrylate (PMMA) which offers favorable esthetic properties, polishability and sufficient short-term wear resistance. The acrylic tooth was chosen based on shade and anatomical compatibility to harmonize with adjacent natural dentition. It was adapted and secured into the edentulous site on the cast to create a provisional tooth contour and emergence profile that closely mimicked the original central incisor (Figure 2).

A 1.0 mm thick thermoplastic sheet (Durasoft PD Clear, SCHEU-DENTAL GmbH, Germany) was selected for the retainer due to its optimal balance between rigidity, flexibility, and translucency. The sheet was vacuum-formed over the modified cast using a pressure-forming unit (Erkopress 300 Tp, Erkodent, Germany) to ensure precise adaptation to the dental arch.

After cooling, the appliance was carefully trimmed using acrylic burs and precision scissors. The margins were polished with silicone points to ensure smooth borders and patient comfort (Figure 3). The final Essix retainer with the embedded acrylic pontic was trial-fitted intraorally to confirm esthetics, fit, and retention (Figure 4).

The patient was instructed to wear the appliance during the day and remove it at night to prevent tissue impingement and allow mucosal rest. Hygiene instructions included daily cleaning with a soft toothbrush and non-abrasive soap, and avoidance of biting into hard or sticky foods to prevent distortion or damage to the appliance. The patient was also advised to store the appliance in water when not in use to prevent dehydration and deformation of the acrylic components.

Follow-up

At the one-week and one-month follow-up appointments, clinical evaluation revealed healthy healing at the implant site with no signs of inflammation or complications. The patient expressed satisfaction with the aesthetics and

Figure 3: Final Essix retainer with incorporated pontic (left central incisor), ready for delivery

Figure 4: Intraoral postoperative view showing Essix retainer with pontic in place, providing aesthetic and functional interim replacement

comfort of the Essix retainer being used as a temporary prosthesis.

Discussion

The Essix retainer with a pontic was selected in this case as an interim prosthesis due to its conservative, aesthetic, and patient-compliant characteristics. Fabricated from a 1.0 mm thick clear thermoplastic sheet. The appliance conforms precisely to the dental arch offering an inconspicuous and visually pleasing solution that requires no tooth preparation or metallic components.[2] This is particularly beneficial in the anterior maxillary region where preserving gingival architecture, interdental papillae, and soft tissue contours is critical to achieving optimal long-term aesthetic outcomes.[3]

One of the key advantages of the Essix appliance is its minimal contact with the edentulous ridge, thus eliminating pressure on the implant site. This facilitates undisturbed osseointegration while still maintaining the space and gingival form required for the future prosthesis.[4] The appliance's lightweight nature, comfort in function, and translucency enhance patient acceptance, particularly among younger or esthetically driven individuals who may be reluctant to wear bulkier removable prostheses.[5]

Alternative interim options were evaluated but ultimately deemed less suitable in this scenario:

Removable acrylic flippers are lightweight and cost-effective but often suffer from poor retention and instability. Their bulk and potential to impinge on soft tissues may compromise peri-implant healing and alter ridge contour.[5]

Removable partial dentures (RPDs) provide enhanced retention but are typically bulkier, can impair speech and comfort, and may exert stress on adjacent teeth and the healing ridge via their clasps and base extensions.[6]

Resin-bonded fixed partial dentures (e.g., Maryland bridges), while more aesthetic and fixed, require preparation of the lingual surfaces of abutment teeth for metal wing bonding. These preparations risk enamel compromise and are technique-sensitive, especially in moist environments. Debonding is not uncommon, particularly in cases with occlusal challenges or parafunctional habits.[7]

In contrast, the Essix retainer with a pontic provides a non-invasive, cost-effective, and biocompatible solution that meets the aesthetic, functional, and biological demands of the interim phase in implant dentistry.[2,3] Its ability to preserve the soft tissue profile, avoid implant site trauma, and ensure patient comfort makes it a preferred choice in many anterior implant cases. Proper case selection is crucial. The Essix appliance is best suited for single missing anterior teeth, particularly when adjacent teeth are intact and patient compliance is expected. It is not recommended in cases requiring long-term temporization beyond the typical osseointegration period or in patients with parafunctional habits.[4]

Conclusion

Essix retainers with a pontic serve as an effective interim prosthetic option in anterior implant cases, offering esthetics, comfort, and soft tissue preservation without compromising the healing process. Their clear thermoplastic design avoids pressure on the surgical site, maintains gingival architecture, and ensures patient compliance. Easy to fabricate and cost-efficient, they are especially beneficial for single missing teeth in esthetically sensitive areas. This technique not only improves patient satisfaction and confidence during the transitional phase but also supports optimal conditions for the final prosthesis.

References

1. Moskow BS, LaMarche MJ, Turek TJ. Essix appliances in clinical practice: conservative aesthetic options. J Esthet Dent. 1997;9(4):131-5.
2. Chopra S, Bansal P, Bansal P. Essix appliance: an innovation modification for use as temporary bridge—a case report. J Adv Med Dent Scie Res. 2020;8(1):184-6.
3. Moskowitz EM, Sheridan JJ, Celenza F Jr, Tovilo K, Muñoz AM. Essix appliances: provisional anterior prosthesis for pre and post implant patients. N Y State Dent J. 1997;63(4):32-5.
4. Glidewell Laboratories. Temporary implant solutions – Essix retainer. Newport Beach (CA): Glidewell Laboratories; 2024. p.1.
5. Pankey Institute. Why use an Essix retainer versus a flipper during dental implant therapy? Key Biscayne (FL): The Pankey Institute; 2023.
6. Jivraj S, Chee W, Corrado P. Treatment planning of the edentulous maxilla. Br Dent J. 2006;201(5):261-9.
7. Hemmings KW, Darbar UR, Vaughan S. Tooth wear treated with direct composite restorations: 20-month follow-up. Br Dent J. 2000;188(3):131-4.